JHWCR JOURNAL OF HEALTH, WELLNESS AND COMMUNITY RESEARCH 3007-0570

https://doi.org/10.61919/9jbstm24

Original Article

Lumbosacral Structural Changes in Patients Presenting with Low Back Pain on LS X-Ray and Its Association with Clinical Symptoms

Ayesha Asim[1], Mahrukh Baig[1], Hameed Jan[1], Maheen Mirza[2], Fiza Fatima[1], Habiba Faryad[1], Noor Hummayoun[1], Wajiha Zafar[3]

[1] BS in Medical Imaging and Ultrasonography, University of Management and Technology, Lahore, Pakistan.

[2] BS in Medical Imaging Technology, University of Management and Technology, Lahore, Pakistan.

[3] Master of Science in Diagnostic Ultrasound, University of Management and Technology, Lahore, Pakistan.

***Corresponding author: Maheen Mirza, maheenmirza1992@gmail.com**

"Cite this Article" Received: 02 February 2026; **Accepted**: 03 March 2026; **Published**: 10 March 2026

Author Contributions: Concept: AA, MB, HJ, MM, FF, HF, NH, WZ; Design: AA, MB, HJ, MM, WZ; Data Collection: AA, MB, HJ, FF, HF, NH; Analysis: AA, MB, HJ, MM, WZ; Drafting: AA, MB, HJ, MM, FF, HF, NH, WZ. **Ethical Approval**: University of Management and Technology, Lahore, Pakistan. **Informed Consent**: Written informed consent was obtained from all participants; **Conflict of Interest**: The authors declare no conflict of interest. **Funding**: No external funding; **Data Availability**: Available from the corresponding author on reasonable request; **Acknowledgments**: N/A.

ABSTRACT

Background: Low back pain is a common musculoskeletal complaint frequently evaluated with plain lumbosacral radiography, although the relationship between radiographic abnormalities and clinical symptoms remains uncertain. Objective: To assess lumbosacral structural changes on plain X-ray in patients with low back pain and determine their association with clinical findings and pain characteristics. Methods: This cross-sectional observational study was conducted in the Radiology Department of Gurkee Hospital, Lahore, and included 150 patients aged above 20 years presenting with low back pain and referred for lumbar spine X-ray. Demographic and clinical variables were recorded, including radiating pain, numbness/tingling, pain duration, onset, pain type, and pain severity. Radiographic assessment included disc space narrowing, osteophyte formation, spondylolisthesis, facet joint degeneration, sacroiliac joint changes, vertebral body deformity, and spinal level involvement. Data were analyzed using descriptive statistics and chi-square testing. Results: The mean age of participants was 46.8 ± 15.7 years, and 53.3% were male. Radiating pain to the legs was reported by 48.7%, while 51.3% had numbness or tingling. Vertebral body deformity was the most frequent radiographic finding (57.3%), followed by spondylolisthesis (53.3%). No statistically significant association was observed between the most prevalent radiographic findings and pain severity or pain duration. Conclusion: Lumbosacral structural changes are common in patients with low back pain, but plain X-ray findings alone do not reliably correspond to symptom severity or duration. Keywords: Low back pain, lumbosacral spine, radiography, vertebral body deformity, spondylolisthesis, clinic radiological association.

INTRODUCTION

Low back pain is one of the most prevalent musculoskeletal complaints worldwide and remains a major contributor to disability, reduced productivity, and impaired quality of life across diverse age groups. Recent global estimates indicate that hundreds of millions of individuals are affected, with the burden expected to rise further because of population growth and ageing, making low back pain a substantial public health and health-systems challenge (1,2). Although low back pain is clinically common, its underlying mechanisms are heterogeneous and may involve a complex interaction among degenerative spinal changes, cumulative mechanical loading, tissue sensitization, inflammation, occupational exposure, and psychosocial stressors rather than a single anatomical abnormality alone (3-5).

Structural alterations within the lumbosacral spine are frequently evaluated when patients present with low back pain, particularly in routine clinical settings where plain radiography remains widely available,

ISSN 3007-0570 | © 2026 The Authors | CC BY 4.0

affordable, and commonly requested. Among the abnormalities often described on lumbosacral imaging are disc space narrowing, osteophyte formation, spondylolisthesis, facet joint degeneration, sacroiliac joint changes, and vertebral body deformity. Degenerative disc changes may emerge over time through repetitive loading, age-related tissue dehydration, and progressive biomechanical remodeling, potentially contributing to altered force transmission across the lumbar spine (3,6). However, the clinical meaning of these radiographic findings remains uncertain because structural abnormalities may also be detected in individuals with minimal symptoms, while some patients with severe pain demonstrate limited radiographic change. This discordance suggests that radiological appearance alone may not adequately explain symptom severity or functional complaint and should be interpreted within a broader clinical context (3,4,6). Occupational and psychosocial exposures further complicate this relationship. Repetitive bending, heavy lifting, prolonged postural loading, and physically demanding work have been linked to lumbar degenerative changes and chronic symptom development, while stress, burnout, and adverse workplace conditions may influence pain perception, chronicity, and reporting behavior (7,8). These interacting pathways indicate that low back pain is not simply a radiographic condition and that structural findings visible on plain X-ray may represent only one component of a multidimensional clinical problem. For this reason, determining the extent to which commonly observed lumbosacral radiographic changes correspond with patient-reported symptoms remains clinically important, particularly in settings where X-ray is used as an initial imaging modality (9,10)

Previous research has shown that plain lumbosacral radiographs often reveal degenerative or nonspecific abnormalities in adults with low back pain, yet the correlation between such findings and clinical presentation is inconsistent. In a primary care-based study, abnormal lumbosacral radiographs were common, but the practical diagnostic value of plain radiography in explaining symptoms remained limited, especially when interpreted without comprehensive clinical assessment (11). Despite growing literature on the epidemiology and burden of low back pain, there remains a relative shortage of studies that directly and systematically compare routine lumbosacral X-ray findings with the severity and pattern of presenting symptoms in the same patient population, particularly in local hospital-based contexts. This gap is important because overinterpretation of radiographic changes may influence diagnostic labeling and management decisions without necessarily improving clinical care. The present study was therefore designed to evaluate lumbosacral structural changes identified on plain X-ray in patients presenting with low back pain and to determine their association with key clinical features, including pain severity, symptom duration, radiating pain, and sensory complaints. It was hypothesized that although structural abnormalities would be frequently observed on radiography, their association with clinical symptom severity would be limited (12,13).

MATERIALS AND METHODS

A hospital-based cross-sectional observational study was conducted in the Radiology Department of Gurkee Hospital, Lahore, to assess the association between clinical symptoms of low back pain and structural changes detected on plain lumbosacral radiography. This design was selected because it allowed simultaneous evaluation of presenting clinical characteristics and radiographic findings within a defined patient population undergoing routine imaging for diagnostic assessment. The study focused on adult patients referred for lumbosacral spine X-ray because plain radiography remains a commonly used first-line imaging tool in routine practice despite recognized limitations in explaining symptom severity when used in isolation (14).

The study included patients aged more than 20 years who presented with low back pain and were referred for lumbar spine X-ray examination. Patients were excluded if they had a history of prior spinal injury, spinal trauma within the preceding six months, known metabolic bone disease, pregnancy, or marked spinal curvature misalignment that could interfere with interpretation of standard lumbosacral radiographs. Participants were recruited from patients presenting during the study period who met the

eligibility criteria and agreed to participate. Before enrolment, each participant was informed about the purpose and procedures of the study, and written informed consent was obtained.

Clinical and demographic data were collected using a structured proforma at the time of presentation. Recorded variables included age, sex, radiating pain to the legs, numbness or tingling, duration of pain, onset of pain, type of pain, and pain severity. Pain severity was assessed using the Numerical Rating Scale and was subsequently categorized as mild, moderate, or severe for descriptive and comparative analysis. Pain duration was grouped into less than 1 month, 1-3 months, 3-6 months, and more than 6 months. The anatomical level involved was documented as L1-L2, L2-L3, L3-L4, L4-L5, or L5-S1 according to the radiographic assessment. The principal radiographic variables of interest were disc space narrowing, osteophyte formation, spondylolisthesis, facet joint degeneration, sacroiliac joint changes, and vertebral body deformity, all of which represent commonly reported structural abnormalities in patients undergoing lumbar spine imaging for low back pain evaluation

Radiographic data were obtained using routine plain lumbar spine radiography in anteroposterior and lateral projections. Before imaging, participants were instructed to remove metallic objects such as buttons and zippers to minimize image artifacts, and relevant safety screening was performed. For the anteroposterior projection, patients were positioned supine on the X-ray table with the midsagittal plane centered to the midline of the table and the shoulders and hips maintained in parallel alignment to avoid rotation. For the lateral projection, patients were positioned on their side with slight flexion of the hips and knees, with additional support under the knees as required to maintain comfort and positioning accuracy. Radiographs were then assessed for the predefined structural abnormalities and the lumbar level involved.

To improve data quality and reduce information bias, the study used a standardized data collection proforma and a predefined set of radiological variables for all participants. Eligibility criteria were applied uniformly to limit the inclusion of patients with alternative causes of lumbar pain that could confound the observed clinicoradiological relationship. Because the objective of the study was exploratory association rather than causal inference, the analytical plan emphasized transparent descriptive reporting and comparison of symptom categories across radiographic findings. The sample size comprised 150 participants, consistent with the study target used for the cross-sectional analysis.

All data were entered and analyzed using Statistical Package for the Social Sciences. Descriptive statistics were used to summarize demographic characteristics, symptom patterns, spinal levels involved, and radiographic findings. Categorical variables were presented as frequencies and percentages, while continuous variables were summarized using mean and standard deviation where appropriate. Associations between categorical radiographic findings and clinical variables, including pain severity and pain duration, were assessed using the chi-square test. A p-value of less than 0.05 was considered statistically significant. The analysis was primarily descriptive and bivariate in nature, and results were presented in tables and figures to facilitate interpretation of the distribution of abnormalities and their relationship with clinical presentation. The study was conducted in accordance with institutional ethical requirements. Ethical guidance from the University of Management and Technology was followed, and approval was obtained from the local ethical committee of Gurkee Hospital, Lahore. Participation was voluntary, written informed consent was secured from all participants, and confidentiality of patient information was maintained throughout data collection, handling, and reporting. No identifying information was disclosed in the manuscript, and all data were retained solely for research purposes.

RESULTS

A total of 150 participants with low back pain were included in the analysis. The mean age of the sample was 46.8 ± 15.7 years, with the largest proportion belonging to the 20-30 year age group (23.3%), followed by the 41-50 year group (20.7%). Male participants were slightly more frequent than female participants, accounting for 53.3% and 46.7% of the sample, respectively. Clinically, radiating pain to the legs was

reported by 48.7% of participants, while numbness or tingling was reported by 51.3%, indicating that radicular or sensory-type symptoms were common in nearly half of the study population. Regarding pain chronicity, 34.7% of patients had symptoms for less than 1 month, whereas 25.3% had pain for more than 6 months. Pain onset was gradual in 51.3% and sudden in 48.7% of participants. With respect to pain character, sharp pain was the most frequent pattern (22.0%), followed closely by stabbing pain (21.3%) and numbness/tingling-type pain descriptors (20.7%). Pain severity was relatively evenly distributed, with 35.3% classified as mild, 30.0% as moderate, and 34.7% as severe. The most commonly involved spinal level was L3-L4 (24.0%), while L4-L5 and L5-S1 each accounted for 20.7% of cases.

Table 1. Baseline Demographic and Clinical Characteristics of Participants

Variable	Category	Frequency (n)	Percentage (%)
Age group	20-30 years	35	23.3
	31-40 years	22	14.7
	41-50 years	31	20.7
	51-60 years	24	16.0
	61-70 years	27	18.0
	71-80 years	11	7.3
Gender	Male	80	53.3
	Female	70	46.7
Radiating pain to legs	Yes	73	48.7
	No	77	51.3
Numbness/tingling	Yes	77	51.3
	No	73	48.7
Pain duration	<1 month	52	34.7
	1-3 months	27	18.0
	3-6 months	33	22.0
	>6 months	38	25.3
Onset of pain	Gradual	77	51.3
	Sudden	73	48.7
Pain type	Burning	27	18.0
	Dull	27	18.0
	Numbness/tingling	31	20.7
	Sharp	33	22.0
	Stabbing	32	21.3
Severity of pain	Mild	53	35.3
	Moderate	45	30.0
	Severe	52	34.7
Level involved	L1-L2	30	20.0
	L2-L3	22	14.7
	L3-L4	36	24.0
	L4-L5	31	20.7
	L5-S1	31	20.7

The radiographic profile demonstrated that structural abnormalities were highly prevalent overall. Vertebral body deformity was the most frequent radiological finding, present in 57.3% of participants, followed by spondylolisthesis in 53.3%. Sacroiliac joint changes were observed in 50.7%, osteophyte formation in 49.3%, disc space narrowing in 48.7%, and facet joint degeneration in 48.0%. The distribution of radiographic findings was therefore relatively broad, with all six assessed abnormalities present in approximately half of the sample, suggesting that degenerative or structural changes on plain lumbosacral X-ray were common among patients presenting with low back pain.

Table 2. Distribution of Radiological Findings on Lumbosacral X-Ray

Radiological finding	Absent n (%)	Present n (%)
Disc space narrowing	77 (51.3)	73 (48.7)
Osteophyte formation	76 (50.7)	74 (49.3)
Spondylolisthesis	70 (46.7)	80 (53.3)
Facet joint degeneration	78 (52.0)	72 (48.0)
Sacroiliac joint changes	74 (49.3)	76 (50.7)
Vertebral body deformity	64 (42.7)	86 (57.3)

When the two most prevalent radiological findings were compared across pain severity categories, no statistically significant associations were identified. Spondylolisthesis was present in 54.7% of participants with mild pain, 51.1% with moderate pain, and 53.8% with severe pain, yielding a p-value of 0.93. Vertebral body deformity showed a similarly stable pattern, being present in 60.4% of mild cases, 53.3% of moderate cases, and 57.7% of severe cases, with a p-value of 0.78. These data indicate that although both abnormalities were common, their frequency did not increase consistently with higher pain severity and therefore did not show evidence of a meaningful clinicoradiological gradient in this sample.

Table 3. Association of the Most Prevalent Radiological Findings with Pain Severity

Radiological finding	Category	Mild n (%)	Moderate n (%)	Severe n (%)	p-value
Spondylolisthesis	Absent	24 (45.3)	22 (48.9)	24 (46.2)	0.93
	Present	29 (54.7)	23 (51.1)	28 (53.8)	
Vertebral body deformity	Absent	21 (39.6)	21 (46.7)	22 (42.3)	0.78
	Present	32 (60.4)	24 (53.3)	30 (57.7)	

A similar pattern was observed when these radiographic abnormalities were assessed against pain duration. Spondylolisthesis was present in 61.5% of participants with pain duration of less than 1 month, 37.0% of those with pain lasting 1-3 months, 51.5% of those with pain for 3-6 months, and 55.3% of those with pain for more than 6 months. Despite this variation, the association was not statistically significant ($p = 0.22$). Vertebral body deformity was present in 51.9%, 63.0%, 60.6%, and 57.9% of the same duration categories, respectively, and again showed no significant association with pain duration ($p = 0.77$). Taken together, these findings suggest that the presence of these common structural abnormalities on plain X-ray did not reliably distinguish between either more severe pain or longer symptom duration in the studied population.

Table 4. Association of the Most Prevalent Radiological Findings with Pain Duration

Radiological finding	Category	<1 month n (%)	1-3 months n (%)	3-6 months n (%)	>6 months n (%)	p-value
Spondylolisthesis	Absent	20 (38.5)	17 (63.0)	16 (48.5)	17 (44.7)	0.22
	Present	32 (61.5)	10 (37.0)	17 (51.5)	21 (55.3)	
Vertebral body deformity	Absent	25 (48.1)	10 (37.0)	13 (39.4)	16 (42.1)	0.77
	Present	27 (51.9)	17 (63.0)	20 (60.6)	22 (57.9)	

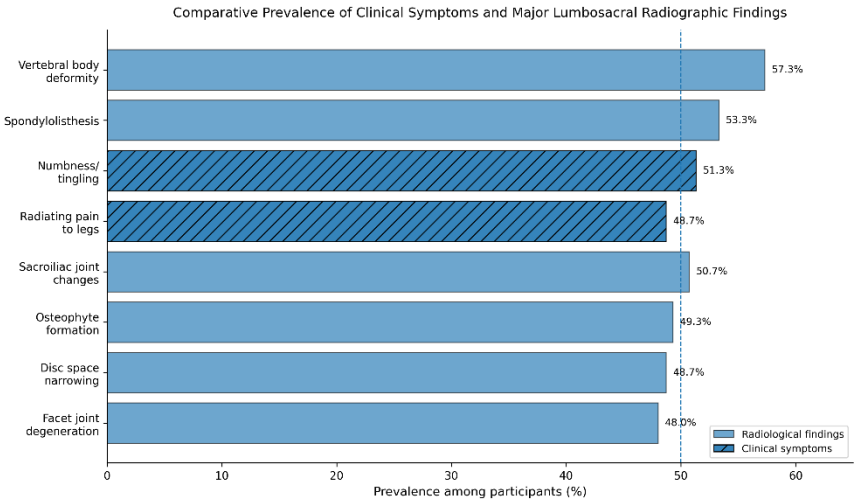

Figure 1 Prevalence profile demonstrated a tightly clustered burden of abnormalities and symptoms

Overall, the results show that structural changes on lumbosacral X-ray were frequent but clinically nonspecific in this cohort. Vertebral body deformity exceeded the 50% prevalence threshold by 7.3 percentage points, and spondylolisthesis exceeded it by 3.3 percentage points, while sensory symptoms such as numbness/tingling were also highly prevalent at 51.3%. In contrast, radiating pain to the legs remained just below this threshold at 48.7%. Despite this substantial burden of both symptoms and radiographic abnormalities, the absence of statistically significant associations across pain severity and

pain duration indicates that routine lumbosacral X-ray findings alone may have limited value in explaining symptom intensity or chronicity in patients presenting with low back pain.

The comparative prevalence profile demonstrated a tightly clustered burden of abnormalities and symptoms around the 50% threshold, with vertebral body deformity showing the highest prevalence at 57.3%, followed by spondylolisthesis at 53.3% and numbness/tingling at 51.3%. Sacroiliac joint changes were present in 50.7%, while osteophyte formation, disc space narrowing, radiating pain to the legs, and facet joint degeneration ranged from 48.0% to 49.3%. The narrow spread between the highest and lowest values was only 9.3 percentage points, indicating that both structural findings and symptom manifestations were broadly common across the cohort rather than dominated by a single pathological pattern. Clinically, this distribution supports the interpretation that common lumbosacral X-ray abnormalities coexist with symptom burden but do not, on their own, establish a clear severity gradient.

DISCUSSION

The present study evaluated the relationship between structural abnormalities identified on plain lumbosacral radiography and the clinical presentation of patients with low back pain. The findings showed that radiographic abnormalities were common in this cohort, with vertebral body deformity and spondylolisthesis being the most prevalent, yet these changes were not significantly associated with either pain severity or pain duration. This pattern is clinically important because it reinforces the concept that structural abnormalities visible on plain X-ray may coexist with symptoms without necessarily explaining their intensity or chronicity. Low back pain is increasingly understood as a multifactorial condition in which pain generation is influenced not only by anatomical changes but also by age-related degeneration, occupational load, tissue sensitivity, biomechanical adaptation, and psychosocial context (1-5). The absence of a significant clinic radiological association in the present data therefore supports a broader biopsychosocial interpretation of low back pain rather than a purely structural model.(15)

The demographic profile of the study population was broadly consistent with the established epidemiology of low back pain. The mean age of 46.8 years indicates that the sample was concentrated in midlife, a period during which both symptom burden and degenerative spinal changes become increasingly common. Previous literature has shown that lumbar degenerative findings rise with age, particularly beyond the fourth decade of life, even in community-based populations, which may partly explain why radiographic abnormalities were frequent in the present study irrespective of symptom severity (16). The slight predominance of male participants in this cohort contrasts with some prior reports that have documented a higher proportion of female patients presenting with low back pain in primary care settings, suggesting that sex distribution may vary according to referral pathways, occupational exposures, and the local clinical population rather than reflecting a universal pattern (17).

The clinical symptom pattern observed in this study also deserves attention. Nearly half of the patients reported radiating pain to the legs, and just over half described numbness or tingling, indicating that symptom extension beyond localized low back discomfort was common. However, even with this relatively high burden of potentially radicular or neuropathic-type complaints, the most prevalent radiographic abnormalities did not show a statistically meaningful association with symptom severity or duration. This mismatch may reflect the limited ability of plain radiography to capture soft tissue, neural, discal, and inflammatory contributors to pain. Plain X-ray is useful for identifying gross structural change, alignment abnormalities, vertebral deformity, and certain degenerative findings, but it cannot directly evaluate many clinically relevant pain generators, including nerve root compression, disc hydration status, annular pathology, ligamentous injury, or muscular dysfunction (18). As a result, the presence of radiographic changes alone should not be assumed to represent the source of patient symptoms.

The findings of this study are in general agreement with previous work suggesting that abnormal lumbosacral radiographs are frequent among patients with low back pain but have limited explanatory

value when interpreted in isolation. AlAteeq et al. reported that degenerative changes were common on plain lumbosacral X-ray, yet the clinical utility of these findings was restricted because many abnormalities were nonspecific and not always clearly linked to symptom presentation (19). The present results extend that observation by showing that even the most frequent findings in this cohort, particularly vertebral body deformity and spondylolisthesis, remained distributed rather evenly across mild, moderate, and severe pain categories, with p-values of 0.78 and 0.93, respectively. Similarly, no significant relationship was found between these abnormalities and pain duration, further supporting the interpretation that common radiographic changes may reflect background degenerative processes rather than a direct measure of symptom burden.

From a clinical perspective, these findings argue against overreliance on routine lumbosacral X-ray for explaining severity of pain in patients presenting with low back pain. When radiographic abnormalities are highly prevalent in both milder and more severe symptom groups, their isolated presence becomes difficult to interpret as a marker of clinical status. This is especially relevant in routine care settings where imaging findings may inadvertently influence diagnostic labeling, patient anxiety, and treatment expectations. The present study therefore supports the principle that imaging should be interpreted alongside detailed clinical history, physical examination, and, where indicated, more advanced modalities capable of assessing soft tissue and neural structures more directly (20). In practical terms, the data suggest that plain X-ray may be more useful for excluding selected structural concerns or documenting gross degenerative change than for predicting symptom intensity.

This study also contributes local evidence to an area where region-specific data remain relatively limited. Much of the literature on low back pain burden focuses on epidemiology, risk factors, and disability trends, whereas fewer studies in comparable routine-care settings directly correlate plain radiographic findings with concurrent symptom characteristics in the same patient group (1,2,7). By examining both clinical and radiological variables within a hospital-based cohort, the present work helps clarify the limits of plain radiography in everyday practice. At the same time, the results should not be interpreted to mean that radiographic findings are irrelevant; rather, they indicate that such findings are insufficient on their own to account for the complexity of low back pain. A patient may have structural change without severe pain, while another may experience substantial symptoms with minimal radiographic abnormality, underscoring the importance of individualized assessment.

The study has several limitations that should be considered when interpreting the findings. It was conducted at a single center and included a moderate sample size, which may limit external generalizability. The cross-sectional design prevents any inference regarding temporal or causal relationships between structural changes and symptoms. In addition, the analysis was based on plain lumbosacral radiography, which may underestimate clinically meaningful pathology not visible on X-ray, particularly soft tissue and neural abnormalities. The study also relied primarily on bivariate comparisons and did not include multivariable adjustment for potentially relevant factors such as body mass index, occupation, comorbidities, or psychosocial stressors, all of which may influence symptom experience and reporting (4,5). Future multicenter studies using larger samples, standardized radiological interpretation, and advanced imaging correlation would provide a more comprehensive understanding of the relationship between spinal structure and clinical symptoms in low back pain.

Overall, the discussion of the present findings supports a cautious and clinically integrated interpretation of lumbosacral radiographs. Structural abnormalities on plain X-ray were frequent, but their lack of significant association with pain severity and duration suggests that they should not be viewed as straightforward proxies for symptom burden. The results align with contemporary understanding that low back pain is a multifactorial condition in which radiographic change is only one part of a larger clinical picture, and they reinforce the need for balanced, patient-centered assessment rather than symptom attribution based solely on routine imaging findings (1-7).

CONCLUSION

Lumbosacral structural abnormalities were common among patients presenting with low back pain, with vertebral body deformity and spondylolisthesis being the most frequent radiographic findings; however, these abnormalities were not significantly associated with pain severity or pain duration in this cohort. The findings indicate that routine plain lumbosacral X-ray may identify prevalent structural changes but has limited value in explaining the intensity or chronicity of clinical symptoms when used in isolation. These results support the need for comprehensive clinical assessment and cautious interpretation of radiographic findings in the evaluation of low back pain.

REFERENCES

1. AlAteeq M, Alseraihi AA, Alhussaini AA, Binhasan SA, Ahmari EA. Plain lumbosacral X-rays for low back pain: findings correlate with clinical presentation in primary care settings. J Family Med Prim Care. 2020;9(12):6115-20.

2. Ferreira ML, De Luca K, Haile LM, Steinmetz JD, Culbreth GT, Cross M, et al. Global, regional, and national burden of low back pain, 1990-2020, its attributable risk factors, and projections to 2050: a systematic analysis of the Global Burden of Disease Study 2021. Lancet Rheumatol. 2023;5(6):e316-e329.

3. Kaneda G, Zila L, Wechsler JT, Shafi K, Cheema K, Bae H, et al. What a pain in the back: etiology, diagnosis and future treatment directions for discogenic low back pain. Bone Res. 2025;13(1):89.

4. Khoshakhlagh AH, Sulaie SA, Yazdanirad S, Orr RM, Laal F. Relationships between job stress, post-traumatic stress and musculoskeletal symptoms in firefighters and the role of job burnout and depression mediators: a bayesian network model. BMC Public Health. 2024;24(1):468.

5. Hong JY, Kim H, Jeon WJ, Yeo C, Kim H, Lee J, et al. Animal models of intervertebral disc diseases: advantages, limitations, and future directions. Neurol Int. 2024;16(6):1788-1818.

6. Larner K. The many facets of spine pathology: a review and evaluation of approaches in biological anthropology and their current and future applications.

7. Linton AA, Hsu WK. A review of treatment for acute and chronic pars fractures in the lumbar spine. Curr Rev Musculoskelet Med. 2022;15(4):259-71.

8. Salo S, Hurri H, Rikkonen T, Sund R, Kröger H, Sirola J. Association between severe lumbar disc degeneration and self-reported occupational physical loading. J Occup Health. 2022;64(1):e12316.

9. Zhang C, Lv B, Yi Q, Qiu G, Wu F. Global, regional, and national burden of low back pain in working-age population from 1990 to 2021 and projections for 2050. Front Public Health. 2025;13:1559355.

10. Tsujimoto R, Abe Y, Arima K, Nishimura T, Tomita M, Yonekura A, et al. Prevalence of lumbar spondylosis and its association with low back pain among community-dwelling Japanese women. BMC Musculoskelet Disord. 2026;17(1):493.

11. Jensen MC, Brant-Zawadzki MN, Obuchowski N, Modic MT, Malkasian D, Ross JS. Magnetic resonance imaging of the lumbar spine in people without back pain. N Engl J Med. 1994;331(2):69–73.

12. van Tulder MW, Assendelft WJ, Koes BW, Bouter LM. Spinal radiographic findings and nonspecific low back pain: a systematic review of observational studies. Spine (Phila Pa 1976). 1997;22(4):427–34.

13. Jarvik JG, Deyo RA. Diagnostic evaluation of low back pain with emphasis on imaging. Ann Intern Med. 2002;137(7):586–97.

14. Kalichman L, Hunter DJ. Lumbar facet joint osteoarthritis: a review. Semin Arthritis Rheum. 2007;37(2):69–80.

15. de Schepper EI, Damen J, van Meurs JB, Ginai AZ, Popham M, Hofman A, et al. The association between lumbar disc degeneration and low back pain: the influence of age, gender, and individual radiographic features. Spine (Phila Pa 1976). 2010;35(5):531–6.

16. Weiner BK, Fraser RD. Foraminal stenosis and disc degeneration in the lumbar spine. Spine (Phila Pa 1976). 1998;23(4):441–6.

17. Boden SD, Davis DO, Dina TS, Patronas NJ, Wiesel SW. Abnormal magnetic-resonance scans of the lumbar spine in asymptomatic subjects. J Bone Joint Surg Am. 1990;72(3):403–8.

18. Modic MT, Ross JS. Lumbar degenerative disk disease. Radiology. 2007;245(1):43–61.

19. Cheung KM, Karppinen J, Chan D, Ho DW, Song YQ, Sham P, et al. Prevalence and pattern of lumbar magnetic resonance imaging changes in a population study of one thousand forty-three individuals. Spine (Phila Pa 1976). 2009;34(9):934–40.

20. Brinjikji W, Luetmer PH, Comstock B, Bresnahan BW, Chen LE, Deyo RA, et al. Systematic literature review of imaging features of spinal degeneration in asymptomatic populations. AJNR Am J Neuroradiol. 2015;36(4):811–6.