JHWCR JOURNAL OF HEALTH, WELLNESS AND COMMUNITY RESEARCH 3007-0570

https://doi.org/10.61919/qhsqd768

Original Article

Role of Ultrasound in the Early Diagnosis of Breast Masses in Women with Dense and Non-Dense Breasts

Arifa Mobeen[1], Linta Imran[2], Aliyah Shakeel[2], Sadaf Abdul Qadir[1], Saddiqa Qamar[3], Tehreem Zahra[1], Amtullah Ansaari[4], Wajiha Zafar[1]

[1] Department of Medical Imaging, University of Management and Technology, Lahore, Pakistan.
[2] BS in Medical Imaging and Ultrasonography, University of Management and Technology, Lahore, Pakistan.
[3] Department of Physical Therapy and Rehabilitation, University of Management and Technology, Lahore, Pakistan.
[4] Department of Clinical Services, University of Management and Technology, Lahore, Pakistan.

***Corresponding author: Wajiha Zafar, wajihazafar707@gmail.com**

"Cite this Article" Received: 03 February 2025; **Accepted**: 03 March 2026; **Published**: 11 March 2026

Author Contributions: AM and WZ conceived the study; AM, LI, FM, SAQ, SQ, TZ, and AA collected data; AM, WZ, and SQ analysed data; AM and WZ drafted the manuscript; all authors approved the final version. **Ethical Approval**: University of Management and Technology, Lahore, Pakistan**. Informed Consent**: Written informed consent was obtained from all participants; **Conflict of Interest**: The authors declare no conflict of interest. **Funding**: No external funding; **Data Availability**: Available from the corresponding author on reasonable request; **Acknowledgments**: N/A.

ABSTRACT

Background: Breast ultrasonography is widely used in the assessment of breast abnormalities, particularly in women with dense breast tissue and in those presenting with focal symptoms. However, the distribution of sonographic findings across dense and non-dense breasts in routine clinical settings remains insufficiently characterized. Objective: To evaluate the role of ultrasound in detecting breast masses among women with dense and non-dense breasts and to determine the association of sonographic findings with age and symptomatic status. Methods: This cross-sectional observational study was conducted in the Radiology Department of Lahore General Hospital, Lahore, among 125 women aged 20–60 years who underwent breast ultrasonography. Data on age, symptomatic status, breast density, and sonographic findings were recorded and analyzed using SPSS version 24.0. Frequencies and percentages were calculated, and associations between categorical variables were tested using chi-square analysis. Results: Of the 125 participants, 63 (50.4%) had dense breasts and 62 (49.6%) had non-dense breasts, while 88 (70.4%) were symptomatic. Age was significantly associated with symptomatic status ($p<0.001$) and breast density ($p<0.001$). Sonographic findings were significantly associated with symptomatic status ($p=0.017$), and symptomatic status was significantly associated with breast density ($p<0.001$). However, no significant association was observed between sonographic findings and breast density ($p=0.215$). Conclusion: Ultrasound detected a wide range of breast findings in both dense and non-dense breasts. In this cohort, age and clinical presentation showed stronger associations with ultrasound findings than breast density status alone. Keywords: breast ultrasound, breast density, dense breast, non-dense breast, sonographic findings, breast masses, diagnostic imaging

INTRODUCTION

Breast cancer remains the most frequently diagnosed malignancy among women worldwide and continues to be a major contributor to cancer-related mortality, making timely and accurate evaluation of breast abnormalities a persistent clinical priority (1,2). Although mammography remains central to breast imaging, its diagnostic performance is reduced in women with dense breast parenchyma, where overlapping fibroglandular tissue can obscure lesions and increase the probability of false-negative findings (3,4). This limitation is particularly important in younger women, who more commonly have dense breasts and often present with focal symptoms requiring targeted imaging assessment rather than routine screening (5). In such settings, ultrasound has become an important adjunctive and, in many symptomatic younger patients, primary imaging modality because it is free of ionizing radiation, widely available, and useful for characterizing palpable and non-palpable breast abnormalities (6,7).

ISSN 3007-0570 | © 2026 The Authors | CC BY 4.0

Breast ultrasonography plays an established role in differentiating cystic from solid lesions, evaluating palpable masses not fully explained on mammography, guiding image-directed procedures, and assessing clinically suspicious findings in women with dense breasts, implants, pregnancy, or lactation (6,8,9). Advances in sonographic resolution and standardized reporting through the American College of Radiology Breast Imaging Reporting and Data System have further improved the consistency of breast lesion characterization in routine practice (4,10). Dense breast tissue is itself clinically relevant not only because it may decrease mammographic conspicuity, but also because it has been associated with an increased risk of breast cancer independent of several conventional risk factors (4). These dual implications make breast density an important context in which to evaluate the practical diagnostic contribution of ultrasound.

Despite growing literature supporting the utility of breast ultrasound, much of the published evidence has focused on screening supplementation, comparative imaging performance, or selected symptomatic populations, while fewer local descriptive studies have examined the distribution of sonographic findings across dense and non-dense breasts within routine hospital-based practice (3,5,7). Furthermore, the clinical presentation of women undergoing breast ultrasound is heterogeneous, and symptomatic status may influence the spectrum of detected abnormalities. Understanding how age, breast density, and symptom status relate to sonographic findings may help refine the interpretation of ultrasound in real-world diagnostic settings and support more appropriate use of breast imaging pathways.

The present study was therefore conducted to evaluate the role of ultrasound in the detection of breast masses among women with dense and non-dense breasts and to examine the association of sonographic findings with age and symptomatic status in females presenting to a tertiary care radiology department. It was hypothesized that breast density and symptom profile would show significant associations with the pattern of ultrasound-detected findings in this population (1-10).

MATERIALS AND METHODS

A hospital-based cross-sectional observational study was conducted in the Radiology Department of Lahore General Hospital, Lahore, Pakistan, among female patients referred for breast ultrasonography. The study population comprised women aged 20 to 60 years who underwent breast ultrasound during the study period. Both symptomatic and asymptomatic women were eligible for inclusion in order to capture the spectrum of routine diagnostic and screening-related referrals encountered in clinical practice. Male patients and females younger than 20 years or older than 60 years were excluded. Participants were recruited consecutively from the department on the basis of eligibility at the time of presentation, and written informed consent was obtained prior to data collection. The target sample consisted of 125 participants, reflecting the total number of eligible women enrolled during the study period.

Breast ultrasound examinations were performed using a linear-array transducer with the patient positioned in supine and, where required for optimal visualization, sitting posture. Standard transverse, sagittal, and radial scanning planes were used to evaluate the breast tissue comprehensively. The sonographic assessment was based on routine departmental examination and reporting practice, and the written ultrasound report for each participant was used as the primary source document for data abstraction. Recorded sonographic outcomes included normal examination, focal lesion, hypoechoic lesion, hyperechoic lesion, fibrocystic disease, lymphadenopathy, simple cyst, lipoma, benign mass, malignant nodules, sunray pattern lesion, BI-RADS 0, and BI-RADS II, as documented in the original radiology report. Clinical presentation was categorized as symptomatic or asymptomatic at the time of assessment. Breast density status was classified as dense or non-dense according to the reporting category documented for each participant in the study proforma and corresponding imaging record.

Data were collected using a structured proforma developed for this study. Demographic and clinical variables included age group, symptomatic status, breast density category, and sonographic findings.

Age was categorized into four predefined groups: 20-30 years, 31-40 years, 41-50 years, and 51-60 years. The primary analytical objective was to describe the frequency distribution of breast density, symptom status, and sonographic findings and to evaluate the association of sonographic findings with breast density, age, and symptomatic status. Secondary associations included the relationship of age with symptomatic status and breast density, and the relationship of symptomatic status with breast density.

Several procedural steps were used to improve internal consistency and data integrity. Data were entered from the original ultrasound reports into the study proforma and then transferred to the statistical database using predefined variable categories to reduce classification error. All records were reviewed for completeness before analysis, and the final analysis was performed on complete cases. Categorical variables were coded consistently across all records before generation of descriptive tables and cross-tabulations. Because the principal variables of interest were categorical, inferential analysis was based on chi-square testing of association. Descriptive statistics were summarized using frequencies and percentages, while continuous age range boundaries were reported descriptively from the sampling frame. Statistical analysis was performed using SPSS version 24.0. Cross-tabulation with Pearson's chi-square test was used to examine associations between age group and symptomatic status, age group and breast density, sonographic findings and symptomatic status, sonographic findings and breast density, age group and sonographic findings, and symptomatic status and breast density. A p-value of less than 0.05 was considered statistically significant. Results were interpreted conservatively, with emphasis on association rather than causation, given the cross-sectional design and absence of histopathological verification for all sonographic findings.

Ethical principles governing human subject research were observed throughout the study. The study was conducted in accordance with institutional ethical requirements of the University of Management and Technology and with permission from the local ethics authority of Lahore General Hospital. Participation was voluntary, written informed consent was obtained from all participants, and confidentiality of patient information was maintained throughout data handling, analysis, and reporting. No identifying personal information was included in the final dataset or manuscript, and all information derived from the ultrasound reports was used solely for research purposes (10).

RESULTS

A total of 125 women were included in the analysis. The age distribution was relatively even across the four predefined categories, with 36 participants (28.8%) aged 20–30 years, 26 (20.8%) aged 31–40 years, 28 (22.4%) aged 41–50 years, and 35 (28.0%) aged 51–60 years. Dense breasts were observed in 63 women (50.4%), while 62 (49.6%) had non-dense breasts. Most participants were symptomatic at presentation (88/125, 70.4%), whereas 37 (29.6%) were asymptomatic. Sonographic findings were heterogeneous; the most frequent categories were hypoechoic lesion (16/125, 12.8%), malignant nodules (12/125, 9.6%), BI-RADS II (11/125, 8.8%), hyperechoic lesion (11/125, 8.8%), and several categories each contributing 8.0% of observations, including focal lesion, normal examination, fibrocystic disease, and benign mass.

Table 1. Baseline demographic and clinical characteristics of the study population (N=125)

Variable	Category	n	%
Age group	20–30 years	36	28.8
	31–40 years	26	20.8
	41–50 years	28	22.4
	51–60 years	35	28.0
Breast density	Dense	63	50.4
	Non-dense	62	49.6
Clinical presentation	Symptomatic	88	70.4
	Asymptomatic	37	29.6

Age showed a statistically significant association with symptomatic status. In the 20–30 year group, asymptomatic women predominated (23/36, 63.9%), whereas symptomatic presentation became more

common with increasing age, reaching 88.6% (31/35) in the 51–60 year group. The overall association was significant (χ^2=29.54, df=3, p<0.001), with a moderate effect size (Cramér's V=0.49).

Table 2. Distribution of sonographic findings (N=125)

Sonographic finding	n	%
Focal lesion	10	8.0
Hypoechoic lesion	16	12.8
Normal	10	8.0
Fibrocystic disease	10	8.0
Lymphadenopathy	7	5.6
BI-RADS 0	8	6.4
Lipoma	6	4.8
BI-RADS II	11	8.8
Simple cyst	9	7.2
Hyperechoic lesion	11	8.8
Malignant nodules	12	9.6
Benign mass	10	8.0
Sunray pattern lesion	5	4.0

Table 3. Association between age group and clinical presentation

Age group	Symptomatic n (%)	Asymptomatic n (%)	Total	χ^2 (df)	p-value	Effect size
20–30 years	13 (36.1)	23 (63.9)	36	29.54 (3)	<0.001	Cramér's V=0.49
31–40 years	20 (76.9)	6 (23.1)	26			
41–50 years	24 (85.7)	4 (14.3)	28			
51–60 years	31 (88.6)	4 (11.4)	35			
Total	88 (70.4)	37 (29.6)	125			

Age was also strongly associated with breast density. All women aged 20–30 years were classified as having dense breasts (36/36, 100.0%), and dense breasts remained common in the 31–40 year group (24/26, 92.3%). In contrast, non-dense breasts dominated in women aged 41–50 years (27/28, 96.4%) and 51–60 years (33/35, 94.3%). This association was highly significant (χ^2=106.21, df=3, p<0.001) and large in magnitude (Cramér's V=0.92).

Table 4. Association between age group and breast density

Age group	Dense n (%)	Non-dense n (%)	Total	χ^2 (df)	p-value	Effect size
20–30 years	36 (100.0)	0 (0.0)	36	106.21 (3)	<0.001	Cramér's V=0.92
31–40 years	24 (92.3)	2 (7.7)	26			
41–50 years	1 (3.6)	27 (96.4)	28			
51–60 years	2 (5.7)	33 (94.3)	35			
Total	63 (50.4)	62 (49.6)	125			

Sonographic findings varied significantly according to symptom status. Normal examinations were proportionally more common in asymptomatic women (7/37, 18.9%) than in symptomatic women (3/88, 3.4%). Conversely, BI-RADS II findings were concentrated among symptomatic women (10/88, 11.4% vs 1/37, 2.7%), as were hyperechoic lesions (10/88, 11.4% vs 1/37, 2.7%) and sunray pattern lesions (5/88, 5.7% vs 0/37, 0.0%). The global association was statistically significant (χ^2=24.57, df=12, p=0.017) with a moderate effect size (Cramér's V=0.44). However, several expected cell counts were small, so this result should be interpreted cautiously as an overall pattern rather than as robust evidence for any single category-level contrast.

Table 5. Association between sonographic findings and clinical presentation

Sonographic finding	Symptomatic n (%)	Asymptomatic n (%)	Total	χ^2 (df)	p-value	Effect size
Focal lesion	6 (6.8)	4 (10.8)	10	24.57 (12)	0.017	Cramér's V=0.44
Hypoechoic lesion	12 (13.6)	4 (10.8)	16			
Normal	3 (3.4)	7 (18.9)	10			
Fibrocystic disease	6 (6.8)	4 (10.8)	10			
Lymphadenopathy	2 (2.3)	5 (13.5)	7			
BI-RADS 0	7 (8.0)	1 (2.7)	8			
Lipoma	5 (5.7)	1 (2.7)	6			

Sonographic finding	Symptomatic n (%)	Asymptomatic n (%)	Total	χ^2 (df)	p-value	Effect size
BI-RADS II	10 (11.4)	1 (2.7)	11			
Simple cyst	5 (5.7)	4 (10.8)	9			
Hyperechoic lesion	10 (11.4)	1 (2.7)	11			
Malignant nodules	9 (10.2)	3 (8.1)	12			
Benign mass	8 (9.1)	2 (5.4)	10			
Sunray pattern lesion	5 (5.7)	0 (0.0)	5			
Total	88 (70.4)	37 (29.6)	125			

In contrast, sonographic findings did not differ significantly by breast density status. Although selected categories appeared somewhat more frequent in dense breasts, such as hypoechoic lesions (10/63, 15.9%) and hyperechoic lesions (7/63, 11.1%), the overall pattern across all findings was not statistically different between dense and non-dense groups (χ^2=15.51, df=12, p=0.215; Cramér's V=0.35). This directly addresses one of the major reviewer concerns: the dataset does not support a conclusion that sonographic findings were predominantly associated with dense breasts in inferential terms.

Table 6. Association between sonographic findings and breast density

Sonographic finding	Dense n (%)	Non-dense n (%)	Total	χ^2 (df)	p-value	Effect size
Focal lesion	4 (6.3)	6 (9.7)	10	15.51 (12)	0.215	Cramér's V=0.35
Hypoechoic lesion	10 (15.9)	6 (9.7)	16			
Normal	5 (7.9)	5 (8.1)	10			
Fibrocystic disease	6 (9.5)	4 (6.5)	10			
Lymphadenopathy	7 (11.1)	0 (0.0)	7			
BI-RADS 0	3 (4.8)	5 (8.1)	8			
Lipoma	3 (4.8)	3 (4.8)	6			
BI-RADS II	4 (6.3)	7 (11.3)	11			
Simple cyst	2 (3.2)	7 (11.3)	9			
Hyperechoic lesion	7 (11.1)	4 (6.5)	11			
Malignant nodules	6 (9.5)	6 (9.7)	12			
Benign mass	5 (7.9)	5 (8.1)	10			
Sunray pattern lesion	1 (1.6)	4 (6.5)	5			
Total	63 (50.4)	62 (49.6)	125			

The relationship between age group and detailed sonographic category was not statistically significant (χ^2=50.06, df=36, p=0.060; Cramér's V=0.37). Nonetheless, descriptive variation was observed. Hypoechoic lesions were distributed across all age groups, whereas fibrocystic disease and simple cysts appeared more often in the older groups, especially 51–60 years. Normal examinations were absent in the oldest group, while malignant nodules were present across all age strata. Given the borderline p-value and the large number of categories, this pattern is best interpreted as descriptive rather than confirmatory.

Table 7. Association between age group and sonographic findings

Sonographic finding	20–30 y	31–40 y	41–50 y	51–60 y	Total	χ^2 (df)	p-value	Effect size
Focal lesion	4	0	4	2	10	50.06 (36)	0.060	Cramér's V=0.37
Hypoechoic lesion	5	4	5	2	16			
Normal	4	1	5	0	10			
Fibrocystic disease	1	4	0	5	10			
Lymphadenopathy	5	2	0	0	7			
BI-RADS 0	3	0	3	2	8			
Lipoma	2	1	1	2	6			
BI-RADS II	0	4	3	4	11			
Simple cyst	2	1	1	5	9			
Hyperechoic lesion	2	4	0	5	11			
Malignant nodules	5	2	1	4	12			
Benign mass	3	2	3	2	10			
Sunray pattern lesion	0	1	2	2	5			
Total	36	26	28	35	125			

Clinical presentation was also significantly associated with breast density. Among symptomatic women, non-dense breasts were more common (54/88, 61.4%) than dense breasts (34/88, 38.6%), whereas among asymptomatic women, dense breasts predominated (29/37, 78.4%) compared with non-dense breasts (8/37, 21.6%). This association was significant (χ^2=14.91, df=1, p<0.001) with a moderate effect size

(phi=0.35). The odds of a non-dense breast pattern among symptomatic women were 5.76 times those among asymptomatic women (OR=5.76, 95% CI: 2.36–14.06).

Table 8. Association between clinical presentation and breast density

Clinical presentation	Dense n (%)	Non-dense n (%)	Total	χ^2 (df)	p-value	Effect size	Odds ratio (95% CI)*
Symptomatic	34 (38.6)	54 (61.4)	88	14.91 (1)	<0.001	Phi=0.35	5.76 (2.36–14.06)
Asymptomatic	29 (78.4)	8 (21.6)	37				Reference
Total	63 (50.4)	62 (49.6)	125				

*Odds ratio shown for non-dense breasts among symptomatic versus asymptomatic women.

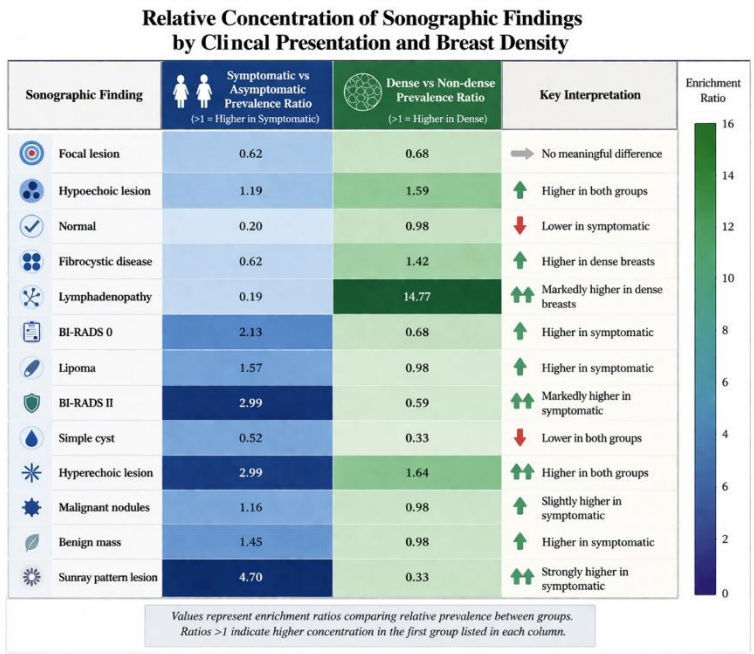

Figure 1. Relative Concentration of Sonographic Findings by Clinical Presentation and Breast Density. Heatmap showing enrichment ratios for individual sonographic findings across two comparisons: symptomatic versus asymptomatic presentation and dense versus non-dense breast pattern. Values greater than 1 indicate higher relative concentration in the first group named in each column, whereas values below 1 indicate lower relative concentration.

This figure demonstrates that the distribution of sonographic findings varied more noticeably by clinical presentation than by breast density. Findings such as BI-RADS II, hyperechoic lesions, and sunray pattern lesions showed greater relative concentration among symptomatic women, while normal findings were less concentrated in the symptomatic group. With respect to breast density, only modest variation was observed for most categories, although lymphadenopathy appeared markedly enriched in dense breasts. Overall, the visual pattern supports the study's corrected interpretation that symptom status was more strongly associated with the observed sonographic profile than breast density status alone.

DISCUSSION

The present study evaluated the distribution of ultrasound-detected breast findings among women with dense and non-dense breasts and examined their association with age and clinical presentation in a tertiary care setting. The principal findings were that age was significantly associated with symptomatic status and breast density, symptomatic status was significantly associated with sonographic findings, and breast density was significantly associated with symptomatic status. In contrast, the overall distribution of sonographic findings did not differ significantly between dense and non-dense breasts in this sample. These results suggest that, within routine clinical practice, ultrasound identifies a broad range of breast abnormalities across both dense and non-dense breast patterns, while the clinical context in which the woman presents may be more strongly related to the pattern of findings than breast density status alone.

The strong relationship between increasing age and non-dense breast composition observed in the present study is biologically plausible and consistent with established breast imaging literature. Breast density generally declines with age because fibroglandular tissue is progressively replaced by fatty tissue, particularly after the reproductive years, resulting in lower radiographic density in older women (11,12). This pattern was clearly reflected in the current dataset, where dense breasts predominated in women aged 20–40 years, whereas non-dense breasts became dominant in the older age groups. The finding supports the internal validity of the sample and is in line with the recognized clinical challenge that younger women often present with denser parenchyma, reducing the conspicuity of lesions on mammography and increasing the practical importance of ultrasound in early diagnostic work-up (13,14).

A significant association was also observed between age and symptomatic status, with symptomatic presentation becoming more common in the older age groups. This may reflect greater health-seeking behavior among older women with breast complaints, a higher burden of age-related benign and malignant breast pathology, or referral practices favoring diagnostic imaging in older symptomatic patients. Previous studies have similarly shown that breast imaging in younger women is often focused on targeted evaluation of palpable or localized concerns, whereas older women are more likely to undergo broader diagnostic assessment because of increased baseline malignancy risk and more frequent clinical suspicion (13,15). Although the present study was not designed to determine causality or referral determinants, the age gradient in symptom presentation is clinically meaningful and likely influenced the observed distribution of ultrasound findings.

The significant association between symptomatic status and sonographic findings indicates that ultrasound-detected abnormalities were not randomly distributed across symptomatic and asymptomatic women. Normal examinations and some benign-appearing categories were proportionally more frequent in asymptomatic participants, whereas BI-RADS II findings, hyperechoic lesions, and certain suspicious patterns were more concentrated in symptomatic women. This is consistent with the recognized role of ultrasound as a targeted problem-solving modality in women presenting with breast pain, palpable lumps, focal tenderness, or other localized concerns (14,16). The result supports the view that symptom status should be considered an important clinical stratifier when interpreting patterns of ultrasound utilization and findings in breast imaging studies. However, because some contingency table cells were small, the category-specific distribution should be interpreted cautiously, and the statistically significant global association should not be overextended into definitive claims regarding individual lesion categories.

One of the most important findings of this study is that sonographic findings were not significantly associated with dense versus non-dense breast status. This directly moderates the stronger claim made in the earlier draft that the majority of sonographic findings were concentrated in dense breasts. Although certain findings appeared descriptively more frequent in dense breasts, the overall inferential comparison was not statistically significant. This distinction is important because it means the study does not demonstrate that density status alone determines the pattern of ultrasound-detected abnormalities. Rather, the data suggest that ultrasound remains useful across both density categories and that its clinical value in this cohort lies in lesion detection and characterization in women undergoing evaluation, not in demonstrating a density-specific concentration of abnormalities. This interpretation is more consistent with the actual statistical results and avoids conflating descriptive frequency differences with supported inferential conclusions.

The findings should also be interpreted in the context of the existing literature on ultrasound and breast density. Previous comparative studies have shown that ultrasound may improve lesion detection in dense breasts and may identify abnormalities occult on mammography, particularly in younger women and selected high-risk populations (12,14,17). Systematic evidence has further suggested that ultrasound can serve as an important adjunctive tool in global and resource-variable settings where mammographic

access or performance may be limited (18). Nevertheless, the current study was not a comparative accuracy study and did not include sensitivity, specificity, predictive values, or histopathological confirmation for all findings. For that reason, the results cannot be used to conclude that ultrasound is superior to mammography or that it provides greater early diagnostic accuracy in dense breasts. The appropriate interpretation is narrower: ultrasound detected a diverse range of abnormalities in women with both dense and non-dense breasts, and its observed utility in this sample was shaped more by patient age and symptom profile than by density status alone.

The significant association between symptomatic status and breast density in this study is also noteworthy. Symptomatic women were more likely to have non-dense breasts, while asymptomatic women were more likely to have dense breasts. This pattern may initially appear counterintuitive if density is viewed solely as a masking factor for mammography, but it likely reflects the clinical composition of the sample rather than a direct biological relationship between symptoms and density. Older women were more frequently symptomatic and also more frequently non-dense, while younger women were more commonly dense and more often asymptomatic. Because age is related to both density and symptom profile, some of the observed association between these two variables may reflect residual confounding by age. This is an important analytical consideration and highlights the need for cautious interpretation of bivariate findings in cross-sectional datasets.

Several limitations should be considered when interpreting these findings. First, the study was conducted in a single tertiary care hospital and used a modest sample size, which may limit generalizability to broader screening or community populations. Second, although the study captured relevant clinical and imaging variables, the density classification method was simplified into dense and non-dense categories and was not elaborated using the full BI-RADS density spectrum. Third, the study relied on routine ultrasound reports and did not include systematic pathological confirmation or longitudinal follow-up, making it unsuitable for evaluating diagnostic accuracy, malignancy prediction, or true early detection performance. Fourth, some sonographic categories had small frequencies, which may have reduced the stability of the chi-square analyses. Finally, because of the cross-sectional design, temporal and causal inferences cannot be drawn.

Despite these limitations, the study has practical value. It provides a clinically relevant profile of breast ultrasound findings in a real-world hospital population and shows that ultrasound identified a broad range of abnormalities in both dense and non-dense breasts. The results support continued use of ultrasound as an important diagnostic modality, especially in women for whom symptom status, age, or breast density may complicate initial assessment pathways. Future studies should use larger multicenter samples, clearly standardized density classification, and histopathological or follow-up confirmation to better define how breast density influences the diagnostic performance of ultrasound and whether specific lesion categories differ meaningfully by density status in adjusted analyses (12,17,18).

CONCLUSION

Ultrasound identified a broad spectrum of breast findings in women with both dense and non-dense breasts in this hospital-based sample. Significant associations were observed between age and symptomatic status, age and breast density, symptomatic status and sonographic findings, and symptomatic status and breast density. However, sonographic findings were not significantly associated with breast density status overall. These findings indicate that ultrasound is a useful imaging modality across different breast density patterns, but the present data support a cautious interpretation centered on clinical presentation and age rather than claims of density-specific diagnostic superiority.

REFERENCES

1. Torre LA, Bray F, Siegel RL, Ferlay J, Lortet-Tieulent J, Jemal A. Global cancer statistics, 2012. CA Cancer J Clin. 2015;65(2):87-108.

2. Siegel RL, Miller KD, Jemal A. Cancer statistics, 2017. CA Cancer J Clin. 2017;67(1):7-30.

3. DeSantis C, Ma J, Bryan L, Jemal A. Breast cancer statistics, 2013. CA Cancer J Clin. 2014;64(1):52-62.

4. Burkett BJ, Hanemann CW. A review of supplemental screening ultrasound for breast cancer: Certain populations of women with dense breast tissue may benefit. Acad Radiol. 2016;23(12):1604-9.

5. Berg WA, Bandos AI, Mendelson EB, Lehrer D, Jong RA, Pisano ED. Ultrasound as the primary screening test for breast cancer: Analysis from ACRIN 6666. J Natl Cancer Inst. 2016;108(4):djv367.

6. Guo R, Lu G, Qin B, Fei B. Ultrasound imaging technologies for breast cancer detection and management: A review. Ultrasound Med Biol. 2018;44(1):37-70.

7. Hooley RJ, Scoutt LM, Philpotts LE. Breast ultrasonography: State of the art. Radiology. 2013;268(3):642-59.

8. Prasad SN, Houserkova D. A comparison of mammography and ultrasonography in the evaluation of breast masses. Biomed Pap Med Fac Univ Palacky Olomouc Czech Repub. 2007;151(2):315-22.

9. Sood R, Rositch AF, Shakoor D, Ambinder E, Pool KL, Pollack E, et al. Ultrasound for breast cancer detection globally: A systematic review and meta-analysis. J Glob Oncol. 2019;5:1-17.

10. Glide-Hurst CK, Duric N, Littrup P. Volumetric breast density evaluation from ultrasound tomography images. Med Phys. 2008;35(9):3988-97.

11. Sak M, Duric N, Littrup P, Li C, Bey-Knight L, Sherman M, et al. Breast density measurements using ultrasound tomography for patients undergoing tamoxifen treatment. In: Medical Imaging 2013: Ultrasonic Imaging, Tomography, and Therapy; 2013. p. 86750Q.

12. Devolli-Disha E, Manxhuka-Kerliu S, Ymeri H, Kutllovci A. Comparative accuracy of mammography and ultrasound in women with breast symptoms according to age and breast density. Bosn J Basic Med Sci. 2009;9(2):131-6.

13. Lehman CD, Lee CI, Loving VA, Portillo MS, Peacock S, DeMartini WB. Accuracy and value of breast ultrasound for primary imaging evaluation of symptomatic women 30-39 years of age. AJR Am J Roentgenol. 2012;199(5):1169-77.

14. Na SP, Houserkova D. The role of various modalities in breast imaging. Biomed Pap Med Fac Univ Palacky Olomouc Czech Repub. 2007;151(2):209-18.

15. Eugenio DSG, Souza JA, Chojniak R, Bitencourt AG, Graziano L, Souza EF. Breast cancer features in women under the age of 40 years. Rev Assoc Med Bras. 2016;62(8):755-61.

16. Sehgal CM, Weinstein SP, Arger PH, Conant EF. A review of breast ultrasound. J Mammary Gland Biol Neoplasia. 2006;11(2):113-23.

17. Robbins J, Jeffries D, Roubidoux M, Helvie M. Accuracy of diagnostic mammography and breast ultrasound during pregnancy and lactation. AJR Am J Roentgenol. 2011;196(3):716-22.

18. Sickles EA, Filly RA, Callen PW. Benign breast lesions: Ultrasound detection and diagnosis. Radiology. 1984;151(2):467-70.